

# A Clinical, Histological, and Computer-Based Assessment of the Polaris LV, Combination Diode, and Radiofrequency System, for Leg Vein Treatment

Neil S. Sadick, MD, FACP, FAACS<sup>1\*</sup> and Mario A. Trelles, MD, PhD<sup>2</sup>

<sup>1</sup>Clinical Professor of Dermatology, Weill Medical College of Cornell University, New York, New York

<sup>2</sup>Instituto Médico Vilafortuny, Fundación Antoni de Gimbernat, Cambrils, Spain

**Background and Objectives:** Electro-optical synergy (ELOS<sup>TM</sup>) is a novel technology that combines radiofrequency (RF) with optical energy. This study investigated the safety and effectiveness of the Polaris LV<sup>TM</sup> system, which is based on combined RF and diode laser (915 nm), for the treatment of leg veins.

**Study Design/Materials and Methods:** Fifty women (Fitzpatrick II–IV) with red or blue leg veins (1–4 mm in diameter) were treated with the Polaris LV, using a fluence of 60–80 J/cm<sup>2</sup> and conducted RF energy of 100 J/cm<sup>3</sup>. Patients received up to three treatment sessions at 2- to 4-week intervals. Both patients and an independent physician graded the level of vessel clearance at 2 months following the last treatment, using pre- and post-treatment photographs. Also, a computer-generated assessment of vessel clearance was done in 40 patients. Twenty patients provided biopsy specimens for histologic assessment.

**Results:** Approximately three-quarters of patients demonstrated ≥50% vessel clearance, and about 30% had 75%–100% vessel clearance. Computer-generated scores correlated closely with physician scores. Histologic assessment showed signs of coagulation and prominent endothelial degeneration in all treated vessels, but the epidermis remained normal. There were minimal complications.

**Conclusions:** The Polaris LV is effective and safe in treating red and blue leg veins up to 4 mm in diameter. *Lasers Surg. Med.* 00:1–7, 2005. © 2005 Wiley-Liss, Inc.

**Key words:** radiofrequency; diode laser; leg vein; telangiectasia; blood vessel; reticular vein

## INTRODUCTION

Lasers and intense pulsed light technologies are being increasingly used to treat unsightly leg veins. In many cases, their safe and effective use has been limited to class I superficial reddish telangiectases [1–3]. Laser light treatment of class II and III deeper bluish venulectases and reticular veins in the lower extremities has been more difficult, with results generally inconsistent and less favorable than the gold standard of sclerotherapy [4–7]. An important reason for this is that lasers do not address the high-pressure reflux from associated feeder veins, which can prevent effective photothermal coagulation. Also, the success of laser light treatment can be limited by

the skin's tolerance to the energy level required for photothermal destruction of the vessel.

Laser therapies are continually being refined to improve the safe and effective eradication of lower extremity vessels, taking into account specific vessel color, size, and depth. Many optical variables must be considered [8–10]. Longer wavelengths (800–1,100 nm) are more specifically absorbed by deoxygenated bluish vessels and allow deeper penetration of light into the dermis. Larger vessel diameters require longer pulse durations to ensure that the vessel wall absorbs enough energy to thermocoagulate its entire luminal surface. Larger spot sizes penetrate deeper into tissue and optimize fluence delivery to the target vessel. Indeed, the 1064-nm Nd:YAG laser, which addresses many of these variables, has emerged as one of the leading technologies for the treatment of deeper and larger-sized leg veins [11].

Electro-optical synergy (ELOS<sup>TM</sup>) is a newly developed technology that combines bipolar radiofrequency (RF) (electrical energy) with optical energy, using either diode laser or an intense pulsed light source. The premise of ELOS is that the two forms of energy may act synergistically to achieve selective thermolysis [12], although clinical studies proving this synergy has not been published to date. For the treatment of leg veins, the ELOS-based system is the Polaris LV<sup>TM</sup> (Syneron Medical Ltd., Yokneam, Israel), which delivers optical energy using a high-power diode laser set at a wavelength of 915 nm and can generate fluences up to 140 J/cm<sup>2</sup>. RF energy is delivered almost simultaneously at levels up to 100 J/cm<sup>3</sup>. Following the selective heating achieved with the laser component, the RF energy is preferentially absorbed by the blood vessel as a result of the increased tissue temperature (brought about by the laser) as well as the high electrical conductivity of blood [12]. With the handpiece, contact cooling to 5°C enhances selectivity and protects the epidermis. Ultimately, the blood vessel reaches a sufficient temperature level that causes permanent injury to the target blood vessel.

The purpose of the present study is to investigate the safety and effectiveness of the Polaris LV<sup>TM</sup> system for the

\*Correspondence to: Neil S. Sadick, MD, FACP, FAACS, 772 Park Avenue, New York, NY 10021.

E-mail: nssderm@sadickdermatology.com

Accepted 16 November 2004

Published online in Wiley InterScience

(www.interscience.wiley.com).

DOI 10.1002/lsm.20127

treatment of leg veins. The study design incorporates the use of a computer program that evaluates image-tissue indices for an objective assessment of the level of vessel clearance, based on pre- and post-treatment digital photographs.

## SUBJECTS AND METHODS

Fifty female patients were enrolled from two private practice settings: Study Site I,  $n = 40$  (MA Trelles, Cambrils, Spain) and Study Site II,  $n = 10$  (Sadick Dermatology, New York, NY). Women were between 24 and 64 years of age (mean age, 41 years) with Fitzpatrick skin types II–IV (Table 1). Treated leg veins were red or blue in color and measured between 1 and 4 mm in diameter. Vessel diameter was recorded as either 1–2 or 3–4 mm. Exclusion criteria included pregnancy, photosensitivity, diabetes, use of anticoagulants, history of bleeding coagulopathies, and scarring. Fourteen of the patients had previously received treatments with sclerotherapy and had refractory vessels that were not treated for 3 months prior to enrolling into the study.

All patients were treated with the Polaris LV<sup>TM</sup> system (Syneron Medical Ltd.). The parameters on this system are as follows: diode laser 915 nm wavelength, fluence up to 140 J/cm<sup>2</sup>, fixed spot size of 5 × 8 mm, RF energy up to 100 J/cm<sup>3</sup>, up to 300 milliseconds pulse width (automatically selected based on energy selection), 1.0 Hz repetition rate, and contact cooling at 5°C.

Prior to therapy, the treatment site was hydrated and cooled with the application of a water-based coupling gel (Aquasonic Clear Ultrasound Gel). The optical energy density used was 60 J/cm<sup>2</sup> at Study Site I and 80 J/cm<sup>2</sup> at Study Site II. RF energy was set at 100 J/cm<sup>3</sup>. Each treatment site received 1–3 passes. Treatment was guided by target vessel reaction and the level of patient discomfort. Pulses were applied using a forwards–backwards technique, which is described as follows: the sapphire guide is placed at the first point of the target vessel to cool, moved to the second point to cool, and then returned to the first point

and fired; moved forwards again to the second point to cool, moved to the third point to cool, and then returned to the second point and fired, etc. In this manner, aggressive epidermal cooling is achieved pre-, intra-, and post-treatment. There is no overlapping of shots. Once the vein is treated with the first pass, if the endpoint has not been reached, then subsequent passes are made until the desired endpoint is seen. The endpoint of treatment goal was vasoconstriction, vessel blanching, and immediate vessel darkening at the target site.

Patients received up to three treatment sessions at 2- to 4-week intervals. Since most patients had multiple leg veins, this was done in order to fully coagulate those vessels that may not have received sufficient energy with the first treatment. Patients were retreated if there was no visible response following the last treatment. No topical anesthetic was utilized. No compression bandages or support stockings were worn. Patients were examined for side effects immediately following treatment, and at 2 weeks, 1 and 2 months post-treatment.

Digital photographs, using high-resolution digital macrophotography (Study Site I, Sony Mavica MVC-FD91 2-mega-pixels; Study Site 2, Fuji Finepix S1 pro, 4 mega-pixels), were taken at baseline and 2 months following the last treatment. Pre- and post-treatment photographs were compared and assessed by an independent vascular surgeon with experience in treating leg veins.

Both patient and physician judged the level of vessel clearance at 2 months after the last treatment. The patient examined the appearance of the treatment site at this time, and compared pre- and post-treatment photographs. The following grading scale was used: very good (VG), 75%–100% vessel clearance; good (G), 50%–<75% vessel clearance; fair (F), 25%–<50% vessel clearance; poor (P), 0%–<25%; or worse (W), if results were worse than the pre-treatment condition. The subjective patient Satisfaction Index (SI) was calculated as the sum of the VG and G scores expressed as a percentage. The vascular surgeon assessing the clinical photography had access only to the photographs and had no knowledge of the patient's score until after his own assessment was made, using the same grading scale as above. The physician rating of the overall efficacy (OE) was calculated in the same way as the patient SI.

Twenty patients from Study Site I provided biopsy specimens from the thigh, which were obtained before, immediately after, and 2 months after the last treatment. Biopsies were done using a 2-mm diameter punch. Care was taken to obtain all specimens from the same vein at the appropriate points, without taking biopsies of the same site twice. Specimens were prepared for routine histology (hematoxylin–eosin stain), connective tissue (Masson trichrome stain), and immunohistochemical staining with an anti-CD34 antibody. Interpretation was carried out by an independent histopathologist.

## Computer Analysis

A computer-based objective analysis was done for the 40 patients enrolled at Study Site I. This is a generic, modular, and expandable computer platform that allows user-

**TABLE 1. Patient and Leg Vein Characteristics**

Parameter	No. of patients (%)
Fitzpatrick skin type	
II	14 (28)
III	24 (48)
IV	12 (24)
Previous sclerotherapy	14 (28)
Vein color	
Blue	28 (56)
Red	22 (44)
Vein caliber	
1–2 mm	24 (48)
3–4 mm	26 (52)
Vein location	
Thigh	28 (56)
Calf	14 (28)
Ankle	8 (16)

friendly image manipulation, sampling extraction, and assisted evaluation of tissue quality, using a novel software [13]. The software is designed to evaluate image-tissue indices and to identify individual or combined descriptors that will more accurately represent differences in vein silhouette.

In the present study, images of the treated area were extracted from the digital photographs at baseline and 2 months after the last treatment, and were processed by the computer software for an objective assessment of vessel clearance. To remove any possible bias through slight differences in ambient illumination and distance conditions, the image samples were automatically normalized, i.e., removing noise, standardizing the brightness, scaling (e.g., adjusting the distance between external markers), and adjusting contrast and luminosity parameters. A Canny operator was used next as an optimal edge detector to closely identify the faint margins of the ruffling veins and to produce an image showing the positions of differences in the tracked intensity. This Canny procedure is combined with a growing region algorithm able to detect the veins area. The images were analyzed to measure the improvement of vessel clearance through the loss of the venous pattern on the skin. The software compared the vessel condition pre- and post-treatment, and scored the improvement in percentages following the same grading scale as that used by the patient and physician.

## RESULTS

All 50 patients completed the study. Fourteen patients (28%) received only 1 treatment; 24 (48%) received 2 treatments; and 12 (24%) received 3 treatments. The initial reaction after treatment usually appeared as vasospasm, followed by erythema above the vessel that lasted about 24–48 hours. Prolonged erythema occurred in some patients but subsided in all cases within 2 weeks. All patients reported varying degrees of pain and discomfort during treatment, which were reported as tolerable. No patient refused further treatment as a result of pain.

Clinical photographs of representative treatment effects are shown in Figures 1 and 2.

Results of the patient and physician assessment of vessel clearance are shown in Table 2. Based on these gradings, the majority of patients achieved at least 50% vessel clearance—76% (36/50) according to patient scoring and 78% (38/50) according to physician scoring. Vessel clearance of 75%–100% occurred in approximately 30% of patients. No patient or physician reported a score of worse. Standardized photographs substantiated these findings (Figs. 1,2). Overall, patient and physician grading of vessel clearance were relatively consistent (within one grade of each other), but the physician tended to score more favorably (by one grade higher in 17 cases) than patients. Five patients scored higher (by one grade) than the physician.

Patients who tended to have greater improvement had required only 1 or 2 treatment sessions. Using patient assessment scores only, a 75%–100% vessel clearance was achieved in 36% (5/14) of patients treated only once, 29% (7/24) of patients treated twice, and 25% (3/12) of patients treated three times. The SI for these three groups was 79% (11/14), 76% (19/24), and 50% (6/12), respectively. There were no noticeable differences in terms of efficacy when the results were stratified by skin type, prior sclerotherapy, vessel location, vessel color, or vessel size.

Transient skin hyperpigmentation was noted in eight patients (20%) and spontaneously faded in all cases by 2 months after the last treatment. There was no correlation between this side effect and skin type. The incidence of treatment-related complications is shown in Table 3. Matting was observed at 2 weeks after treatment in three patients, but was only slightly noticeable in one patient at the 2-month assessment. Blistering was not observed in any patients.

In the 20 patients from whom biopsies were taken, histologic assessment showed normal epidermis and visible vessels before Polaris LV treatment. Immediately after Polaris LV treatment, the epidermis remained normal, but

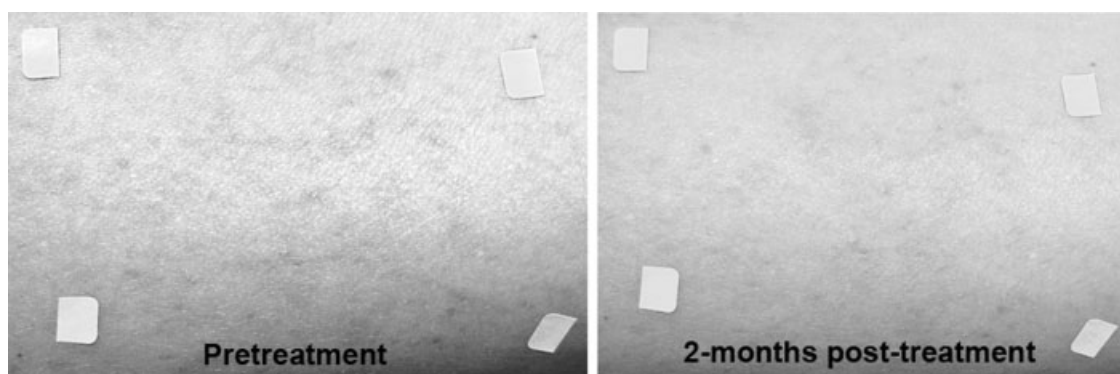


Fig. 1. Pre- and 2-months post-treatment photos of blue 3–4 mm leg veins in a 45-year-old woman (skin type IV) who received two treatment sessions with the Polaris LV (optical =  $80 \text{ J/cm}^2$ ; radiofrequency (RF) =  $100 \text{ J/cm}^3$ ). The patient, physician, and computer evaluations were good, good, and very good, respectively.

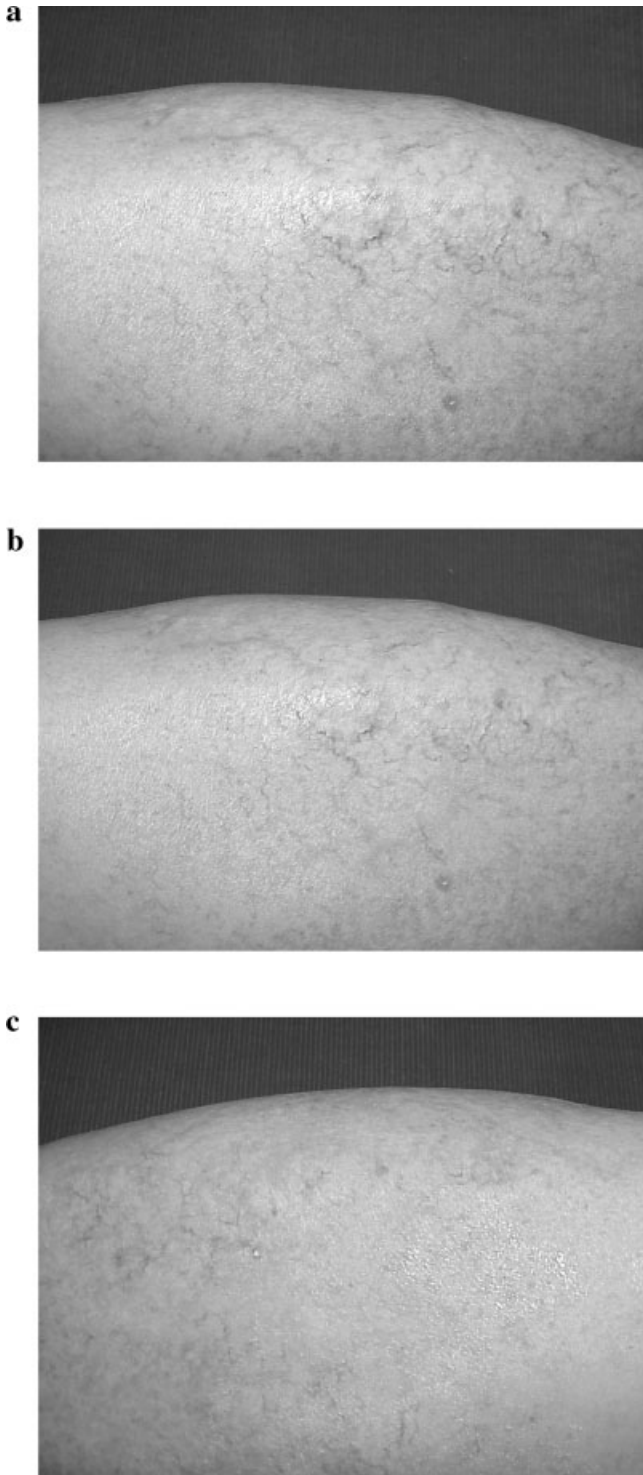


Fig. 2. Photos of leg veins in a 44-year-old woman (skin type II): (a) 4-mm vessels in the thigh before treatment; (b) at 2-weeks post-treatment with the Polaris LV (optical =  $60 \text{ J/cm}^2$ ; RF =  $100 \text{ J/cm}^3$ ), the vessels presented a finer silhouette, and no treatment was given at this time. The area was examined for side effects and none was observed; (c) at 2-months post-treatment, vessels have practically disappeared. The patient, physician, and computer evaluations were all very good.

**TABLE 2. Patient and Physician Assessments of Vessel Clearance at 2 Months Following the Last Treatment (N = 50)**

Grade	Patient	Physician
Very good (75%–100%)	15	19
Good (50%–<75%)	21	19
Fair (25%–<50%)	6	10
Poor (0%–<25%)	8	2
	SI: 36 (72%)	OE: 38 (76%)

SI, Satisfaction Index; OE, overall efficacy. SI and OE calculated as the sum of the very good and good responses. No patient was assessed as “worse.”

there was perivascular collagen necrosis and loss of vessel wall characteristics showing signs of coagulation and prominent endothelial degeneration in all cases. Figure 3 depicts representative histological (Fig. 3a–c) and immunohistochemical findings (Fig. 3d), showing clear closure of the vessels with coaptation and coagulation of the vessel walls and surrounding tissues both in HE and Masson Trichrome staining at 2 months after the final treatment. The immunohistochemical findings showed clusters of disorganized CD34-positive cells indicating destruction of the endothelium of the target vessels.

### Computer Data Results

Computer data were available for the 40 patients in Study Site I. The computer-generated data analysis showed that the majority of vessels changed in silhouette, length, and number following treatment. The most significant changes occurred after the first treatment session. Figure 4 is an example of the computer analysis comparing the vessels as seen in the clinical photograph with the computer edge-detection process before and after treatment, from which the good clearance of these particular vessels can be seen. The computer, using a pixel-based algorithm, is also able to calculate the rate of reduction of the vessel area, as seen in the inset table.

The computer-generated scores for vessel clearance were generally more favorable than the patient and physician assessment scores, but were overall well-matched, particularly with physician scores (Table 4). Computer scores matched in 30 cases with physician scores, compared with 18 cases with patient scores.

Interestingly, in these subset data ( $n = 40$ ), based on computer scores, there was no correlation between number of treatments and vessel response (the SI was 75% in patients receiving only one treatment, 85% in patients receiving two treatments, and 75% in those receiving three treatments). However, blue vessels tended to show better response than red vessels; the SI was 88% and 68%, respectively. Vessel clearance of 75%–100% was achieved in 42% (10/24) of patients with blue vessels and 31% (5/16) of patients with red vessels. Further, when computer scores for vessel diameter were evaluated, the SI was 82% for vessels 3–4 mm in diameter and 76% for vessels 1–2 mm in diameter.

**TABLE 3. Complications From Polaris LV Treatment (N = 50)**

Effect	Side effects immediately after treatment	Complications 2 weeks after treatment	Complications 2 months after treatment
Pain (> 60% on scale)	10	0	0
Bruising	8	0	0
Crusting	2	1	0
Matting	0	3	1
Hypochromia	0	1	0
Hyperpigmentation	0	8	0

## DISCUSSION

The principles behind the use of the Polaris LV, which combines diode laser with conducted RF energy, for the treatment of leg veins are described as follows: the diode laser emits a near-infrared wavelength of 915 nm, which is especially relevant because it matches a tertiary hemoglobin absorption peak at 915 nm. Longer wavelengths enable deeper penetration and are less absorbed by melanin chromophores [14]. The selective heating created by the

diode laser is intensified with the addition of the conducted RF energy [12]. Different from light energy, RF energy is not absorbed by melanin nor is it dependent on any specific wavelength for hemoglobin absorption. Rather, RF energy generates heat from a current of ions that acts according to the physical principle of impedance; that is, electrical current will always follow the path of highest conductivity (or least resistance) [15,16]. Blood has very high electrical conductivity, and higher temperatures correlate with increased conductivity. Therefore, in terms of treating leg veins with ELOS, the RF energy is preferentially absorbed by the target vessel due to both the increased tissue temperatures (produced by the diode laser) as well as the high electrical conductivity of blood. The contact cooling further drives the RF energy to the target vessel by decreasing the conductivity on the surface of the skin. Through the heat created by both the diode laser and RF current, the blood vessel is able to reach a sufficient temperature level to cause irreversible vessel shrinkage or destruction.

In the present study, a number of efficacy assessments were incorporated into the study design, including digital photography, patient and physician assessments, computer-based objective assessment, and histologic effects following treatment with the Polaris LV. Results demonstrated that the Polaris LV is safe and effective for treating venulectases and reticular veins up to 4 mm in diameter. Approximately three-quarters of the treated population showed at least 50% vessel clearance, following 1–3 treatment sessions, and about 30% had 75%–100% vessel clearance. Digital photographs corroborated these findings. The computer-based objective analysis, which showed that 80% of vessels achieved at least 50% clearance, also substantiated the efficacy of the Polaris LV. The computer-generated scores correlated closely with physician scores for vessel clearance. Histologic assessment showed that treatment with the Polaris LV resulted in collagen necrosis and loss of vessel wall integrity, manifested by characteristics, including signs of coagulation and prominent endothelial degeneration in all cases.

Treatment with the Polaris LV was safe. Temporary hyperpigmentation faded in all cases by 2 months after the last treatment. There were minimal complications, despite the absence of anesthesia and no application of compression dressings. Matting was observed in one patient at the 2-month assessment. Blistering did not occur in any patients,

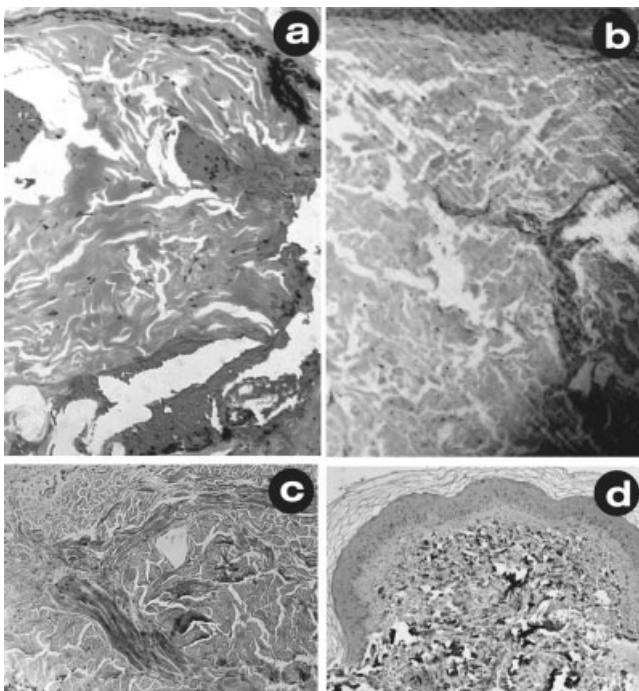


Fig. 3. Representative histological and immunohistochemical findings: (a) pre-treatment findings showing large vessels in a lax dermis (skin H&E, original magnification  $\times 125$ ), (b) immediately after treatment, the vessels are closed and coagulated, with some coagulation also seen in the adjacent dermal collagen (skin H&E, original magnification  $\times 125$ ), (c) Masson's trichrome staining shows a clearly coated and convoluted vessel, with some coagulation of the surrounding dermis, (d) CD34 positively stained cells (dense black) immediately after treatment show the presence of severely damaged, disrupted, and coated vessel endothelial walls.

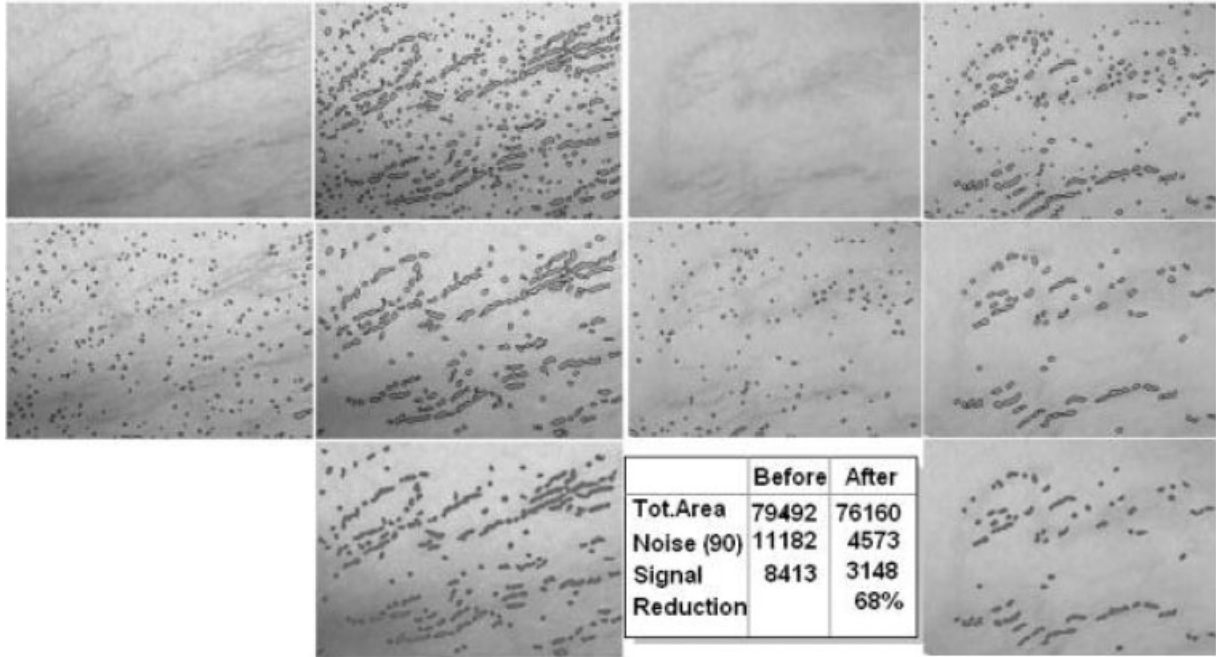


Fig. 4. A representative example of computer-generated images side-by-side with the clinical photography before and 2 months after treatment. The edge-detection process identifies the outlines of the vessels, which are then uniformly filled after noise reduction. The clearance of the vessels is evident. In

addition, the program can calculate the area of the detected vessels using a pixel-based program, as seen in the table in the inset, which indicates an overall reduction of 68% in the vessel area.

and there were no permanent textural or dyschromic sequelae.

To date, one other study from Chess [17] has evaluated the Polaris LV for the treatment of telangiectases, venulectases, and reticular veins. Leg veins up to 5 mm in diameter were treated with up to three sessions at 4- to 10-week intervals. Excellent results were achieved, with approximately 77% of treatment sites ( $N = 35$ ) exhibiting 75%–100% vessel clearance, and 90% exhibiting 50%–100% vessel clearance, at 1 and 6 months after the final treatment. The vessel clearance rates in this study were more favorable than that achieved in the present study. The reason for this may be due to the higher fluences used, ranging from 80 to 120 J/cm<sup>2</sup>, compared with the 60–80 J/

cm<sup>2</sup> set as the optical fluence in the present study. Also, longer intervals between treatment sessions (4- to 10-weeks) versus the 2-week intervals in the present study may have affected outcomes. These are important points that require further study and verification.

It is interesting to note that in the present study, better results were obtained at Study Site II, which used a fluence of 80 J/cm<sup>2</sup>, compared with Study Site I, which used only 60 J/cm<sup>2</sup>. At Study Site II, all treatment sites demonstrated at least 50% vessel clearance, including more than half of vessels exhibiting 75%–100% vessel clearance. These data should be interpreted with caution, however, because of the small number of patients ( $n = 10$ ) that were enrolled from Study Site II.

**TABLE 4. Comparison of Computer Objective Assessment With Patient and Physician Assessments of Vessel Clearance at 2 Months After the Last Treatment ( $n = 40$ )\***

Grade	Patient	Physician	Computer
Very good (75%–100%)	9	14	15
Good (50%–<75%)	17	14	17
Fair (25%–<50%)	6	10	7
Poor (0%–<25%)	8	2	1
	SI: 26 (65%)	OE: 28 (70%)	OE: 32 (80%)

SI, Satisfaction Index, OE, overall efficacy. SI and OE calculated as the sum of the very good and good responses. No patient was assessed as “worse.”

\*All patients were from Study Site I.

Clearly, the settings, methodologies, and technique for use of the Polaris LV still need to be refined for through further studies. However, the findings from this study demonstrate that the Polaris LV system, which combines diode laser with conducted RF, is effective and safe for the treatment of red and blue leg veins up to 4 mm in diameter. In this study, approximately three-quarters of patients treated with the combined modality system had a greater than 50% vessel clearance. Treatment was well-tolerated with minimal complications.

## REFERENCES

1. Kauvar ANB. The role of lasers in the treatment of leg veins. *Semin Cutan Med Surg* 2000;19:245–252.
2. Sadick NS, Weiss RA. The utilization of a new yellow light laser (587 nm) for the treatment of Class I red telangiectasia of the lower extremities. *Dermatol Surg* 2002;28:21–25.
3. West TB, Alster TS. Comparison of the long-pulse dye (590–595 nm) and KTP (532 nm) lasers in the treatment of facial and leg telangiectasias. *Dermatol Surg* 1998;24:221–226.
4. Eremia S, Li C, Umar SH. A side-by-side comparative study of 1064 nm Nd:YAG, 810 nm diode and 755 nm alexandrite lasers for treatment of 0.3–3 mm leg veins. *Dermatol Surg* 2002;28:224–230.
5. Lupton AR, Alster TS, Romero P. Clinical comparison of sclerotherapy versus long-pulsed Nd:YAG laser treatment for lower extremity telangiectases. *Dermatol Surg* 2002;28:694–697.
6. Sadick NS. Updated laser approaches to the management of cosmetic leg veins. *Phlebology* 2003;18:54–64.
7. Weiss RA, Dover JS. Laser surgery of leg veins. *Dermatol Clin* 2002;20:19–36.
8. Goldman MP. Treatment of leg veins with lasers and intensified pulsed light: Preliminary considerations and review of present technology. *Fundament Cosmet Surg* 2001; 19: 467–473.
9. Groot D, Rao J, Johnston P, Nakatsui T. Algorithm for using a long-pulsed Nd:YAG laser in the treatment of deep cutaneous vascular lesions. *Dermatol Surg* 2003; 29: 35–42.
10. Sadick NS. A dual wavelength approach for laser/intense pulsed light source treatment of lower extremity veins. *J Am Acad Dermatol* 2002;46:66–72.
11. Sadick NS. Laser treatment with a 1064-nm laser for lower extremity class I–III veins employing variable spots and pulse width parameters. *Dermatol Surg* 2003;29:916–919.
12. Sadick NS, Makino Y. Selective electro-thermolysis in aesthetic medicine: A review. *Lasers Surg Med* 2004;34: 91–97.
13. Trelles MA, Martin-Vazquez MJ, Trelles O. Objective follow-up by computational evaluation of tissue changes alter light treatment [Abstract #013]. *Lasers Med Sci* 2003;18:S5.
14. Dover JS, Sadick NS, Goldman MP. The role of lasers and light sources in the treatment of leg veins. *Dermatol Surg* 1999;25:328–336.
15. Duck FA. Physical properties of tissue. New York, NY: Academic Press Limited, 1990.
16. Gabriel S, Lau RW, Gabriel C. The dielectric properties of biological tissues: III. Parametric models for the dielectric spectrum of tissues. *Phys Med Biol* 1996;41:2271–2293.
17. Chess C. Prospective study on combination diode laser and radiofrequency energies (ELOS) for the treatment of leg veins. *J Cosmet Laser Ther* 2004;6:86–90.